Archives of Health Science
Case Report

Cerebral Infarct in a Long-Haul Traveller, From a Deep Vein Thrombosis, an Unusual Presentation, In a Person with Patent Foramen Ovale. A Special Case of Paradoxical Embolism

George M. Weisz, MD, FRACS, MA*[1], Richard Haber, MB.BS, FRACP[2], Michael Huang, MB.BS, FRCR, FRANZCR[3],

[1]University of England Armidale and University of New Souths Wales, Sydney.

[2]University of Notre-Dame, Sydney.

[3]Castlereagh Radiology, Sydney. Australia.

***Corresponding Author**: George M. Weisz, MD, FRACS, MA, University of England Armidale and University of New Souths Wales, Sydney, Australia.

Abstract

Whilst brain infarct resulting from leg thrombosis via patent foramen ovale is detailed in the literature, some aspects as selective vertebral artery embolism resulting in celebellarischaemic infarct following a long-haul flight have not yet been described.

The pulmonary embolism induced increased pressure gradient, dominant in the right sided cardiac system, facilitates the transfer of thrombi via the inter-artrial opening. Various organs would be targeted with thrombi, but the present case of thrombus dispersion via subclavian into vertebral artery and resulting in cerebellar ischemia is uncommon. The presenting symptom of seizures has not yet been recorded in thrombotic diseases of the brain. The high mortality rate requires an early aggressive approach of recanalization and cerebral decompression.

Keywords: Paradoxical embolism, long-flight, early diagnosis, anticoagulant.

Introduction

Residual patency of the inter-atrial opening (-formaneovale-) normally closes soon after activation of pulmonary circulation and replaces maternal arterial oxygenation, was reported to be prevalent in between 25% to 35% of the population. The incidence of vertebral artery occlusion induced infarct was found to be between 1-4% of stroke cases, with a remarkably high percentage of mortality.[1] Similar syndromes occur with the presence of congenital atrial septal defect [2,3].

It is remarkable that most cases the Patent Foramen Ovale (PFO) remain unknown, asymptomatic and do not interfere with normal arterial oxygenation [4,5]. However, a transfer of thrombi into the left cardiac system causes widespread arterial embolization. [6-10]. Our case presents with two rare aspects of the embolization:

Case Report

A 54-year-old healthy person travelling in business class landed after a14-hour transpacific flight. His activity during the long flight is unknown and he was not given anti-coagulants. On arrival he collapsed at the airport with tonic-clonic seizure, terminated by injection of midazolam before being flown to a Major Academic Hospital. On arrival at the Emergency Department he was intubated, given Fentanol, later changed to phenytoin.

He was by then unconscious and remained so. He was clinically diagnosed with a cerebellar infarct and considered for posterior fossa decompression. Because of painful reaction to leg compression, he was exposed to Doppler ultrasound test of the legs that revealed deep vein thrombosis. With the suspicion of patent foramen ovale, he was exposed to a trans - esophageal echogram that confirmed the PFO and bi-directional trans-septal bubble flow. CT angiogram diagnosed thrombosis of the vertebral /basilar artery, with extension into PICA, as well as oedema in the posterior fossa and a moderate sized left cerebellar infarct. He was exposed to ECR (endovascular clot retrieval) with successful retrieval of thrombi from the left vertebral artery. Anticoagulants were considered contraindicated, so an IVC filter was inserted. However, with progressive deterioration, a CT demonstrated a trans-tentorial and tonsillar herniation, requiring emergency posterior cranial decompression and C1 laminectomy. All measures proved to beinsufficient and brain death was confirmed on cerebral angiography 2 days after arrival.

The Diagnosis

The figures attached present the sequence of diagnoses and therapy.

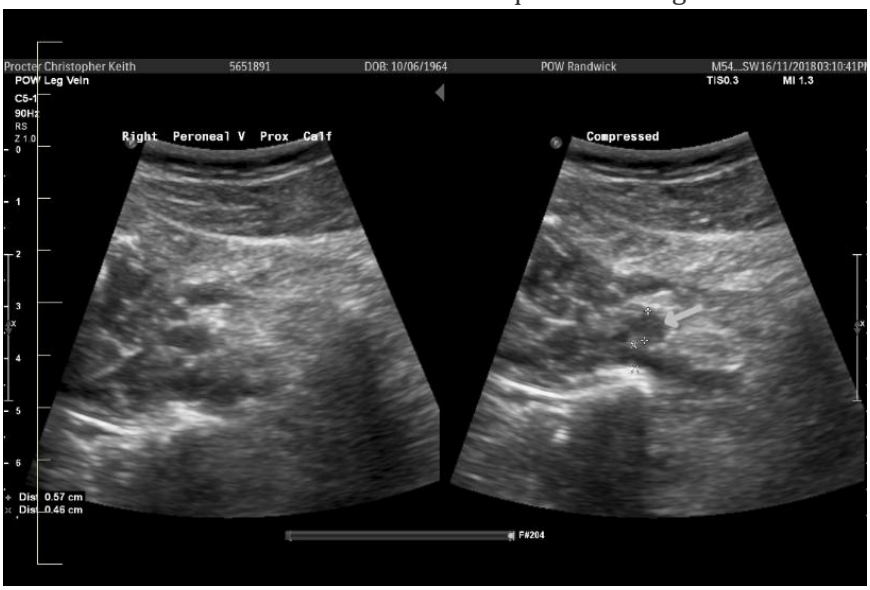

Figure 1: Venous Doppler study showing non compressible thrombus in deep calf Peroneal vein

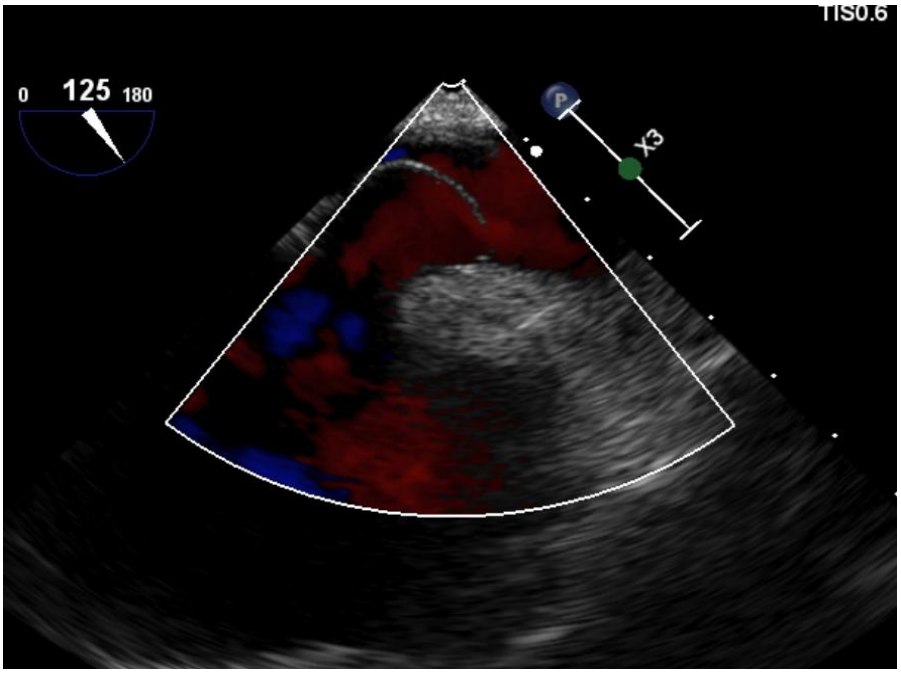

Figure 2: Trans-esophageal echogram showing mixing blood between the two atriums (in colour)

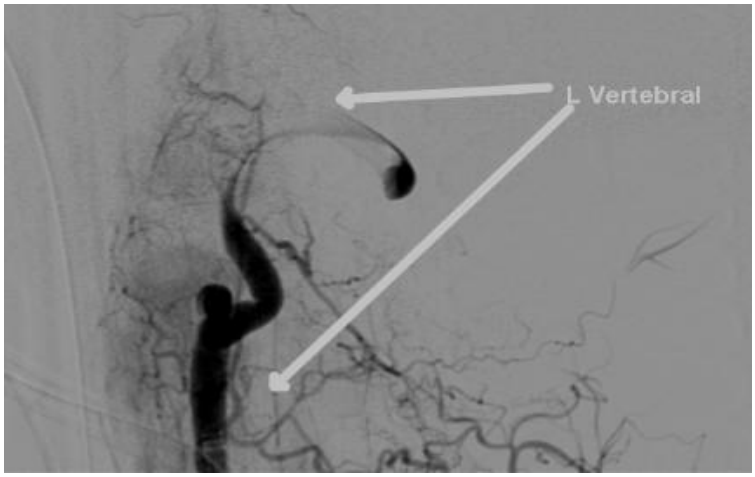

Figure 3a: Vertebral artery clot retrieval embolectomy

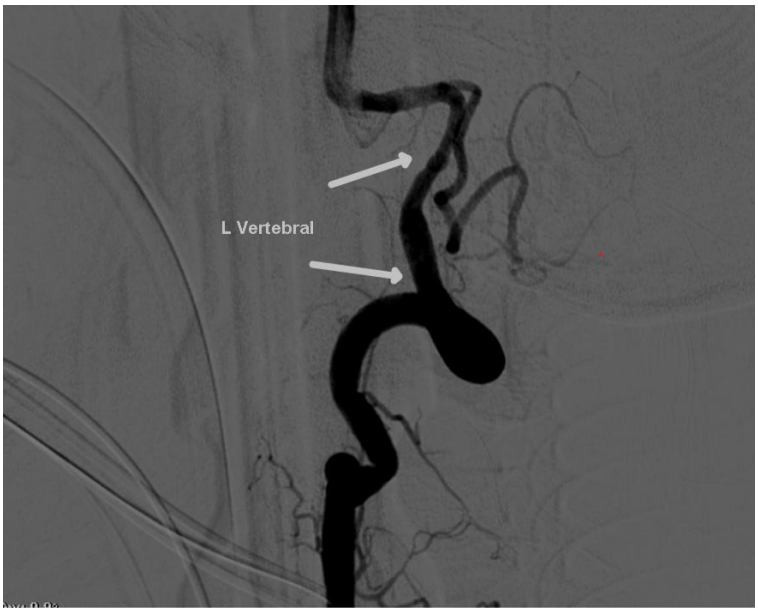

Figure 3b: Artery post embolectomy

Figure 4: Mass effect in left posterior fossa displacing and compressing 4th ventricular

Figure 5: Dilated temporal horns from obstructive hydrocephalus.

Historical Background

The inter-atrial foramen was apparently known since Galen's time in the second century CE. It was presented in the Italian medical publications of the 16 century and also known as "trou de Botal" in the French medical literature of the 19 Century.

It was in the early days of that century that Virchow, the great pathologist, studied thrombosis in Berlin in 1842. The clinical syndrome of embolism was described by H. Wallman in 1859 [11,12]. Studying thrombosis however, it was the well-known clinical pathologist, Julius Cohnheim in Berlin /Leipzig in 1872 who defined the clinical aspect of embolism through the foramen ovale. [13]. Wilhelm Zhan, in 1881 published about "*consequential embolism"* describing the shunt from right to left. It was however the French Amadee Rostand, who in Geneva in 1884, (under Wilhelm Zahn's supervision), presented his doctorate named "*Emboliecroisee*" (crossed) [14]. Surprisingly, a year later, in 1885, the same supervisor, Wilhelm Zahn, published the thesis under his own name as "*Paradoxical embolism*", which remained as a permanent title ever since [15]., (perhaps and expression of a continuous political antagonism between the two nations).

Discussion

The incidence of clinically silent venous thrombosis and the presence of a patent foramen ovale (PFO) was accepted by various researchers as being present in

a 25-35% high percentage of the general population. This opinion suggests that paradoxical emboli may be the cause of an ischemic stroke more often than considered. The subclavian artery trajectory of the cardiac embolus was found to be less encountered within the reviewed literature [11-19].

Most of cryptogenic brain infarcts result from a shift from right cardiac system to the left side, permitted by a patent foramen ovale and allowing for embolism via the wider carotids to the cerebral arterial circle.

Pressure induced embolism was found apart from the thrombotic events, also in various other pathological conditions. It appeared in cases of air and fat embolism, in decompressing deep water divers [20], as well as in the Thurner's anomaly with iliac artery compressing the iliac veins, positioned posteriorly to the arteries rather than anteriorly [21].

Of great interest was the publication of paradoxical embolism originating from pelvic malignancy, ovaries [22] and prostate [23] as well as in various orthopedic prosthetic surgery such as Hip and Knee replacements [24-27]. The recent catastrophic pandemic has not left out its imprint on PFO syndrome and it was reported in young people with Covid 19 leading to acute cerebral infarct [29]. Of intriguing topic was the air travelers with cardiac disease, remaining unresolved [30,31].

In an extensive (NCBI, Google scholar), search of total of 340 papers, we found rare mention of paradoxical embolism via vertebral artery. It is in this case, that PFO permitted transfer of clots originating in the legs after a long-haul flight (despite a greater mobility in business class) and to occlude the left vertebral artery. It led to an emerging cerebellar infarct,which further extended into the central cerebrum, eventually to the pons ischemia and ending with thalamic herniation.

In recent years, embolectomy as an alternative to anti-platelets or anti-coagulant therapy were developed for acute cases. The long-term approach to the foramen ovale itself in recovered cases, remains debatable: to use closure or therapeutics? [32-33].In our case, despite the successful vertebral artery embolectomy, the cranial decompression did not allow for survival. The question could be raised as to whether any anticoagulants (aspirin or Clexane injection for 1-2 days) would have prevented this fatal event, in a person with foramen ovale patent but who was asymptomatic for over 50 years.

Final words

The authors present a case of paradoxical embolism with cerebellar infarct, originating in venous thrombosis of the legs. The specifics are onset of symptoms after a long-haul flight, the presenting syndrome being a clonic (Grand mal) seizure, in a person with unknown patent foramen ovale.

References

[1] Lechat P, et al: Prevalence of patent foramen ovale in young patients with ischemic cerebral complications. NEJM.1988;318(5):1148-52.

[2] Desai A.et al: Patent foramen ovale and cerebrovascular diseases. Nat. Clin. Prac. Cardiovasc. 2006; 3(8):446-55.

[3] Bannan, A, et al: Characteristics of adult patients with atrial septal defects presenting with paradoxical embolism. Catheter Cardiovasc. Interv.2009; 74(7): 1066-9.

[4] Caplan,L R: Brain embolism , revisited. Neurology 1993.43(7): 1281-7.

[5] Chatkof, E L et al: Paradoxical embolism and acute arterial occlusion: rare or unsuspected? J.Vasc Surg.1994;20(3):377-84.

[6] Salam A et al: Unusual presentation of basilar artery stroke secondary to patent foramen ovale: a case report. J. Med. Case Reports. 2008;2:75-82.

[7] Wechsler L R : Advances in treatment of stroke and transient Ischemic Attack. Internal Med. 2020; 67(41):1.

[8] Macdonell RA, et al: Cerebellar Infarction: natural history, prognosis, and pathology. Strokes.1987;18(5):849-55.

[9] Rosman NP, et al: Basillar Artery Occlusion in children. J. Child Neurol. 2003;18:450-62.

[10] Schoen JC et al: Vertebrobasilar Artery Occlusion. West. J. Emerg. Med. 2011; 12(2):233-9.

[11] Elliot G B : Diagnosis of Paradoxical Embolism. Canad. Med.Ass.J. 1962:86,292.

[12] Johnson BI: Paradoxical Embolism. J Clin. Path 1951;4:316-21.

[13] Cohnheim J F: Thrombose und Embolie. Vorlesungen fur Algemeine Pathology. 1877, vol 1.;134

[14] Benaroyo L: Contribution of Friedrich Wilhelm Zahn: Google Scholar 1991.

[15] Rostan Amadee : Contribution a l'etude de L' EmbolieCroisee Geneve. Rivera & Dubois 1884.

[16] Windecker S. et al: Paradoxical embolism. J.Am.Coll.Cardiol. 2014:64(4):403-15.

[17] Ioannides K, et al: Cerebellar Infarct. www.ncbi.nlm.nih.gov/books/NBK470416

[18] Okazaki S, et al: Paradoxical Cerebral Embolism Causing Internal Carotid Artery Occlusion. Internal Med. 46(10): 679-82.

[19] Serena J et al: Patent Foramen Ovale in Cerebral Infarction. Curr. Cardiol.Rev. 2010; 6(3):162-74.

[20] Wilmhust PT et al: Relation between interatrial shunts and decompression sickness in divers. Lancet, 1989;ii:1302-5.

[21] Wada Y, et al: Paradoxical cerebral embolism as an initial symptom in a patient with ovarian cancer. J. Stroke Cerebrovasc Dis. 2007;16(2):88-90.

[22] Rigatelli G , et al: Patent foramen ovale as a preferential mechanism for increasing likelihood of brain tumor metastasis. Am. J. Cardiovasc. Dis.2012: 2(1):29-33..

[23] Della Valle C J. et al: Paradoxical cerebral embolism complicating a major orthopaedic operation. J.Bone & Joint. Surg. (Am). 1999;81(1):108-10.

[24] Narimatsu E, et al : Severe paradoxical intracranial embolism and pulmonary emboli during hip hemiarthroplasty. Br. J. Anesth.2003 91(6): 911-3.

[25] Ogino Y. et al Cerebral infarction after deflation of a pneumatic tourniquet during total knee replacement. Anesthesiol. 1999; 90(1):297-8.

[26] Ashraf M et al: Acute Stroke in a young patient with Coronavirus disease 2019 in the presence of Patent Foramen Ovale. Cureus 2020;13(9):e10233

[27] Balve -Martin A et al.: Thrombotic complications of Severe Covid -19 stroke due to atypical paradoxical embolism. Rev. Neurol,2020: 71(%):186-90.

[28] Lewis MJ et al: Economy Class stroke syndromes: vertebral artery dissection revisited. J.Neurol. Neurosurg. Psychiatry. 2003;74:1593-7.

[29] Beighton P H.et al: Cardiovascular Disease in Air Travellers. Brit. Heart J.1968; 30(3) : 367-72.

[30] Meacham RR, et al: Impending Paradoxical Embolism. Arch Int. Med.; 1998; 158(3):438-48.

[31] Cheng T.: Impending Paradoxical Embolism Arch. Intern. Med. 1998; 158 (15):1720-5.

Citation: George M. Weisz et al., (2021), "Cerebral Infarct in a Long-Haul Traveller, From a Deep Vein Thrombosis, an Unusual Presentation, In a Person with Patent Foramen Ovale. A Special Case of Paradoxical Embolism", Arch Health Sci; 5(1): 1-6.

DOI: 10.31829/2641-7456/ahs2021-5(1)-016

Copyright: *© 2021* George M. Weisz et al., This is an open-access article distributed under the terms of the Creative Commons Attribution License, which permits unrestricted use, distribution, and reproduction in any medium, provided the original author and source are credited.